



PATIENT

Kilo Novoa

SPECIES

Canine

BREED

Rottweiler

SEX

Male Intact

AGE

2.7 years

WEIGHT

120lbs

INTERPRETED BY

Maggie Machen
Lamy, DVM
DACVIM (Cardiology)

IMAGING PERFORMED BY

Pamela Harrigan,
RDCS

HOSPITAL NAME

Anchor Animal
Hospital

REFERRING VET

Dr. Levitt

INVOICE

25870

DATE

8/18/22

PRESENTING CLINICAL SIGNS

History: Presented for trauma following jumping out of a vehicle. PE within normal limits. CXR performed and the LA appeared large. No murmur heard. BP: 193, 195, 199mmHg. Prior resting heart rates recorded as 130, 120 and 110bpm
*Sedated with gabapentin, trazadone, butorphanol for study.

ELECTROCARDIOGRAPHIC FINDINGS *Note: Single lead ECGs are evaluated as a rhythm strip. Morphology/MEA cannot be definitively commented on.

A single lead ECG is available; 25mm/s, 10mm/mV. The average heart rate is 70bpm (range 30-115bpm). The rhythm is sinus in origin, with a p for every QRS complex and vice versa. P and QRS morphologies are positive. Occasional escape foci is seen when the sinus rate slows; escape rate 68bpm. No premature beats, pauses or other dysrhythmias observed.
ECG diagnosis: Sinus bradycardia; rule out high vagal tone versus sedation.

ECHOCARDIOGRAM FINDINGS

2D, m-mode, color flow and Doppler imaging is available.

Left ventricle: The LV diameter is normal with adequate myocardial function. LV wall thicknesses are normal.

Left atrium: The left atrium is normal.

Mitral valve: The mitral valve is normal with trivial MR.

Aortic valve/Aorta: The aortic valve is normal in morphology and mobility. Normal aortic outflow velocity. Trivial aortic insufficiency.

Right ventricle: Normal right ventricular diameter and morphology indicating no overt evidence of pulmonary arterial hypertension.

Right atrium: Normal RA dimension.

Tricuspid valve: The tricuspid valve appears normal with mild tricuspid regurgitation. Normal velocity.

Pulmonic valve/Pulmonary artery: The pulmonic valve is normal in morphology and mobility. Trivial pulmonic insufficiency. Normal RVOT velocity; laminar flow.

Pericardium/other: No obvious cardiac shunts. No pericardial or pleural effusion noted. No obvious cardiac masses.

Heart rhythm: ECG reveals a sinus rhythm with an average HR of 60bpm.

2-Dimensional Measurements

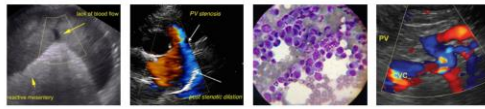
Ao diam (cm)	3.3
LA diam (cm)	3.7
LA:Ao (Swe)	1.3
IVS thickness (cm)	1.2
LVID diastole (cm)	4.9
PW thickness (cm)	1.2
LVID systole (cm)	3.6
FS (%)	27

Doppler Measurements

PV Vmax (m/s)	0.9
AoV Vmax (m/s)	1.3
MR Vmax (m/s)	NA
TR Vmax (m/s)	2.0
TR PG (mmHg)	16

INTERPRETATION OF THE FINDINGS

Overtly normal cardiac dimensions and function. Trivial leaks are noted in all four valves, which are considered physiologic at this time. Follow up is advised should a murmur be



PATIENT

Kilo Novoa

auscultated in the future. No significant valve leaks are noted, and no structural issues identified.

SPECIES

Canine

The ECG is most consistent with high vagal tone. This is likely secondary to sedation (not to mention concurrent illness, young healthy dog, etc); however, if the arrhythmia is noted without sedation, reassessing the ECG is advised. High vagal tone can cause brief sinus pauses/sinus arrest which are seen here. Prior recorded heart rates are normal for a large breed dog, further supporting a dramatic response to sedation as the likely cause.

BREED

Rottweiler

Given these findings the chest radiographs are likely a normal variant and should be used a baseline for further comparison. The patient is notably bradycardic, which is presumably due to sedation. Follow up is advised should bradycardia be noted in the future.

SEX

Male Intact

Prognosis is good.

AGE

2.7 years

The reported blood pressure is elevated and should be reassessed for accuracy particularly given no reported clinical signs of severe hypertension (retinal changes, etc.) or evidence of LVH on echo. Ideally obtain serial measurements in a controlled, low stress environment and continue until 3 consecutive readings plateau within 5mmHg of variability. If persistently >180mmHg despite a relatively calm demeanor, recommend institution of amlodipine to effect. Additionally, if deemed accurate, screening for predisposing underlying causes of SHT is recommended (Cushings, PLN, adrenal tumor, etc.), as primary disease is relatively uncommon and a rule out diagnosis.

WEIGHT

120lbs

INTERPRETED BY

Maggie Machen
 Lamy, DVM
 DACVIM (Cardiology)

RECOMMENDATIONS

- No cardiac medications are indicated.
- Reassess HR/ECG without sedation. If resting HR persists <80bpm and appears inappropriate, consider an exercise and/or atropine response.
- No cardiac contraindication for general anesthesia. If high vagal tone persists, pre-medicate with a vagolytic.
- Monitor for development of a murmur, cough, labored breathing, exercise intolerance or collapse episodes.

IMAGING PERFORMED BY

Pamela Harrigan,
 RDCS

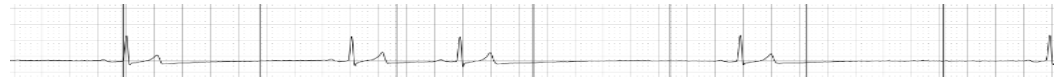
PLAN

- Recommend a recheck echocardiogram should a murmur or clinical signs of cardiac disease develop in the future.

HOSPITAL NAME

Anchor Animal
 Hospital

IMAGES



REFERRING VET

Dr. Levitt

INVOICE

25870

DATE

8/18/22



PATIENT

Kilo Novoa

SPECIES

Canine

BREED

Rottweiler

SEX

Male Intact

AGE

2.7 years

WEIGHT

120lbs

INTERPRETED BY

Maggie Machen
 Lamy, DVM
 DACVIM (Cardiology)

IMAGING PERFORMED BY

Pamela Harrigan,
 RDCS

HOSPITAL NAME

Anchor Animal
 Hospital

REFERRING VET

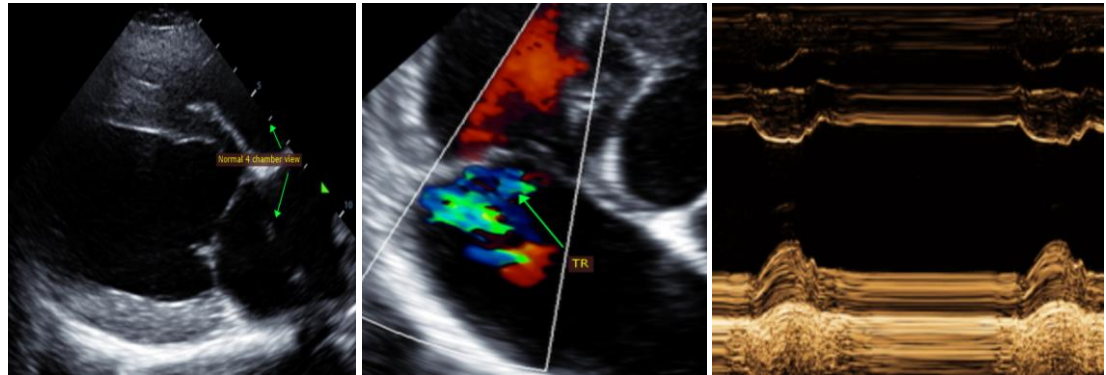
Dr. Levitt

INVOICE

25870

DATE

8/18/22



The information and recommendations provided are based on the images presented by the referring veterinarian. No evaluation can be communicated regarding pathology that was not visible in the image/video clips provided.

Thank you for this referral. This report was generated using transcription software, and minor dictation errors may be present. If the clinical or image interpretation does not parallel your findings or if I can be of any further assistance, please contact me.

Maggie Machen Lamy, DVM
 Diplomate of the American College of Veterinary Internal Medicine (Cardiology)
 info@sonopath.com